

SHORT COMMUNICATION

UDC 577:15+617.584

doi: <https://doi.org/10.15407/ubj91.01.100>

LEVELS OF ANGIOGENIC REGULATORS AND MMP-2, -9 ACTIVITIES IN MARTORELL ULCER: A CASE REPORT

O. M. PETRENKO¹, A. A. TYKHOMYROV²✉

¹Bogomolets National Medical University, Kyiv, Ukraine;

²Palladin Institute of Biochemistry, National Academy
of Sciences of Ukraine, Kyiv, Ukraine;

✉e-mail: artem_tykhomyrov@ukr.net

Received: 27 July 2018; **Accepted:** 13 December 2018

Martorell hypertensive ischemic leg ulcers (HYTILU) represent a unique form of lower extremity non-healing ulcers that develop in association with poorly controlled high blood pressure. The present study was performed in order to assess levels of protein regulators of angiogenesis (vascular endothelial growth factor, or VEGF, and angiostatins) and to evaluate activities of matrix metalloproteinases (MMPs) (gelatinases MMP-2 and -9) in wound cutaneous tissue in the case of patient with 2-years HYTILU history. VEGF and angiostatin levels were analyzed by Western blot, MMP activities were evaluated by gelatin zymography. We report here for the first time that wound tissue in HYTILU is characterized with increased levels of VEGF (by 75 folds vs. histologically normal tissue, $P < 0.01$) and dramatic overproduction of angiostatin levels, which are undetectable in healthy cutaneous tissue. Approximately 10-fold elevation in MMP-2 and -9 activities is observed in wound tissue as compared with uninjured cutaneous tissue. Obtained results indicate that increased production of angiogenic inhibitors, angiostatins, may counteract VEGF-induced pro-angiogenic signaling, and together with MMP overactivation, contributes to failed healing of ischemic ulcer. Further extended studies are needed to clarify how changes of angiogenic profile and imbalance of proteolytic activities in non-healing Martorell ulcers can be considered during their management procedures to improve efficacy of surgery debridement and/or skin grafting.

Key words: Martorell ulcer, chronic wounds, angiogenic regulators, VEGF, angiostatins, MMP.

Martorell hypertensive ischemic leg ulcer (Martorell HYTILU) is an uncommon and poorly underdiagnosed cause of leg ulcers. It represents up to 15% of the leg ulcers hospitalized with dermatology problems. Martorell ulcers are associated with diastolic arterial hypertension in all of patients, and only 58% of them had a diagnosis of diabetes mellitus. Most sufferers are in their 50s and 60s, with a reported age range of 41-86 years [1, 2]. Martorell HYTILU is extremely painful and slowly healing ulcers characterized by localized subcutaneous arteriosclerosis, occlusion of small

vessels, local skin ischemia, and infarction. Though, first described by Martorell, and Hines and Farber in the 1940s, surprisingly little is known about underlying molecular mechanisms of impaired healing of such type of ulcers [3]. There is the scarcity of publications on this issue in Ukraine and no official statistical releases reporting the disease epidemiology.

Proteases are actively involved in wound repair processes, thus the assessment of proteolytic activities is used as biomarkers of wound healing status. Matrix metalloproteinases (MMPs) play a crucial role in various tissue destructive inflammatory pro-

cesses by degrading extracellular matrix proteins and basal membrane components. Among all MMP members, MMP-2 (gelatinase A, EC 3.4.24.24) and -9 (gelatinase B, EC 3.4.24.35) are generally involved in normal tissue remodeling during wound healing [4]. However, overexpression/overactivation of MMPs has been reported to be a key factor of impaired wound healing of diabetic skin ulcers and other vascular complications [5]. Also, MMPs are thought to contribute to poor wound healing and inhibit reparative angiogenesis by generating angiostatsins, which can be cleaved from plasminogen [6]. Angiostatsins can also be produced by limited proteolysis of plasminogen by other proteinases, such as plasmin and neutrophil elastase, resulting in formation of variety of physiologically active fragments containing various number of kringle (K) domains [7]. Angiostatsins induce apoptosis of endothelial cells, effectively inhibit their proliferation and migration. In the context of angiogenic balance, angiostatsins are considered to be one of the major endogenous inhibitors of vessel growth, counteracting pro-angiogenic action of vascular endothelial growth factor (VEGF) and other angiogenic regulators [8]. It is well-established that induction of VEGF expression is of considerable importance for angiogenesis activation in damage tissue to provide a proper wound healing [9]. However, it has been earlier reported that reduced angiogenic capacity of chronic wounds cannot be associated with decreased VEGF expression. Although some leg ulcers expressed enhanced VEGF levels, overproduction of angiogenesis inhibitor, such as angiostatsins and endostatsins, in ulcer environment is thought to contribute to disturbed wound healing [10]. Uncovering molecular events in non-healing wounds, such as Martorell ulcer, would guide clinicians toward better prognostic indicators and better therapeutics for proper ulcer management to get the best results in terms of clinical success and cost saving. Thus, the aim of this study was to assess levels of proteins related to angiogenesis regulation (VEGF and angiostatsins) and to evaluate activities of gelatinases (MMP-2 and -9) in non-healing cutaneous wound tissue of patient with Martorell syndrome. Details are reported herein in this context for the first time.

Materials and Methods

Patient's data and sample preparation. Patient with clinically diagnosed Martorell HYTILU has been taken for this study (Table 1). Our patient gave

Table 1. Patient's medical record

Gender	Male
Age, years	56
Body weight, kg	110
Disease history, duration of disease	Hypertensive ulcer of left leg during 2 years
Blood pressure, mmHg	220/100
Blood glucose level, mmol/l	4.6
Bacterial infection	None
Treatment	Antibiotics, wound dressing, plastic surgery

his written consent before participation in the study and the authorization for the publication of his case. All study procedures and protocols used in this investigation were reviewed and approved by the local ethical committee, and the authors followed all ethical guidelines. The investigations conform to the principles outlined in the latest revision of the Helsinki Declaration (2013).

Five biopsies (approx. 100 mg each) were incised from different regions of ulcer 3.3×4.7 cm of size (Fig. 1) during plastic surgery procedures. As a control, five biopsies, which were proved to be histologically normal tissue, were taken from ulcer surrounding (granulating tissue). All biopate specimens were stored at -80°C until analyzed.

Unless noted otherwise, most chemicals and antibodies were purchased from Sigma Aldrich (USA). Protein samples of tissue specimens for further analysis were prepared by grinding in liquid nitrogen and homogenization in ice-cold 50 mM Tris-HCl buffer (pH 7.4), additionally containing 150

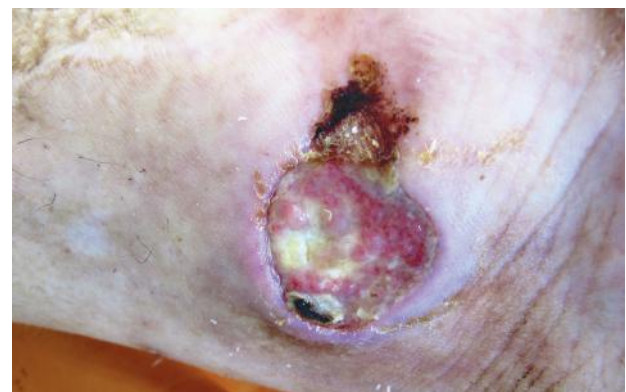

Fig. 1. The studied case of Martorell hypertensive ischemic leg ulcer (HYTILU)

mM NaCl, 0.1% SDS, and supplemented with proteases inhibitor cocktail (6.5 μ M aprotinin, 1.5 μ M pepstatin A, 23 μ M leupeptin, 1 mM phenylmethylsulfonyl fluoride, 5 μ g/ml soybean trypsin inhibitor). Tissue/buffer ratio was taken equal 1:5 (m/v). After homogenisation steps, samples were sonicated for 60 sec by ultrasonic disintegrator Sartorius (Labsonic® M, Göttingen, Germany) and centrifuged at 16,000 g for 45 min at 4 °C. The total protein concentration in each supernatant was determined spectrophotometrically by Stoscheck method measuring absorbance at 260, 280, and 320 nm as described elsewhere [11]. The samples were diluted 1:1 in non-reducing Laemmli Sample Buffer, frozen and stored at -80 °C before analysis.

Immunoblotting. Western blot analysis was used to assess the levels of VEGF and angiostatins. Samples were separated electrophoretically in 10% SDS-PAGE (50 μ g protein per lane). After electroblot transfer onto 0.45 \pm 0.2 μ m pore-size nitrocellulose membranes (Amersham Biosciences, Uppsala, Sweden), the blots were blocked in 5% non-fat dry milk (Apex™ Bioresearch Products, USA, cat. no. 20-241) for 90 min at 37 °C. The blots were then probed with the primary mouse monoclonal anti-VEGF-A (Merck, Germany, cat. no. 05-1117, kind gift of Dr. C.A. Ağca, Bingöl University, Turkey) or rabbit anti-angiostatin antibodies produced as described elsewhere [12] at 4 °C overnight. The membranes were washed in 0.01 M phosphate buffered saline (pH 7.4), containing 0.1% Tween-20 (PBST), and incubated with the appropriate secondary horseradish peroxidase (HRP)-conjugated antibodies (goat anti-rabbit and anti-mouse IgG were from Abcam, USA, cat. nos. ab6721 and ab197767, respectively) for 90 min at 37 °C. Unbound antibodies were washed out in PBST, then the membranes were incubated with HRP substrate and exposed on film (Konica Minolta, Japan). Signals were visualized, digitized, and analyzed using TL120 software (TotalLab Ltd.,

USA). Molecular weights were determined using standard prestained transblot molecular weight markers (PageRuler, cat. no. 26616, Fermentas, Germany). The results were expressed as units of density \times band area and termed as optical density units.

Gelatin zymography. The gelatinolytic activities were analyzed by separating serum proteins (100 μ g/lane) on 8% SDS-PAGE gels copolymerized with gelatin (5 mg/ml), as described earlier [13]. Briefly, after electrophoresis, the gels were washed twice for 30 min in cold 2.5% (v/v) Triton X-100 to remove SDS, and then 5 times for 5 min in cold bi-distilled water. After washing, gels were incubated overnight at 37 °C in developing 50 mM tris-HCl buffer (pH 7.6), containing 0.15 M NaCl, 5 mM CaCl₂, 1 mM ZnCl₂, and 0.02% Tween-20. Zymograms were stained with 0.11 % Coomassie Brilliant Blue R-250 (Merck Millipore, Germany) solution in 30% methanol and 10% acetic acid and destained in the same solution lacking Coomassie Blue. The final gel had a uniform blue background except in those regions to which MMPs had migrated and cleaved the substrate. The gelatinolytic activities were identified as transparent bands against the background of Coomassie Blue-stained gelatine. Resulting MMP bands were visualized and quantified densitometrically.

Statistical analysis. All variables were expressed as mean \pm S.E.M. U Mann-Whitney test was used to evaluate significant differences between mean parameters in ulcer and normal tissues. For all tests, $P < 0.01$ was considered statistically significant. "OriginPro 8.6" (OriginLab Corp., USA) was used to perform all statistical calculations.

Results and Discussion

Western blot of VEGF from the samples of normal and ulcer tissues is depicted in Fig. 2. The abundance of the major VEGF polypeptides of the Mm ~42 kDa and less expressed lower VEGF subu-

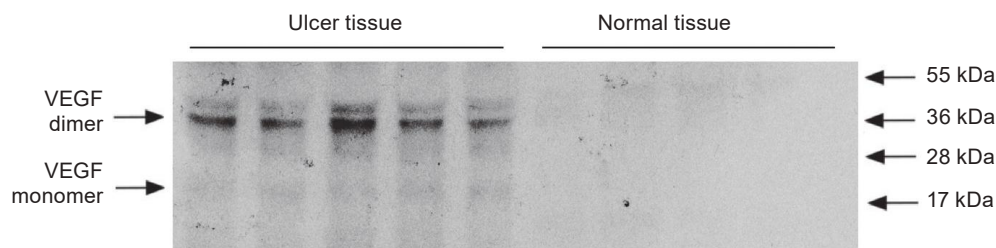


Fig. 2. Western blot analysis of VEGF protein levels in skin wound and normal cutaneous bioplate specimens from the patient with Martorell ulcer

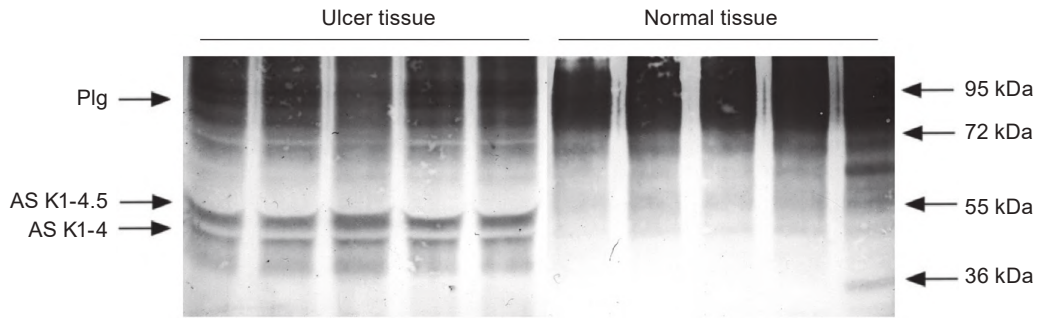


Fig. 3. Western blot analysis of angiostatin levels in skin wound and normal cutaneous bioplate specimens from the patient with Martorell ulcer (Plg – plasminogen, AS – angiostatin)

nit (~21 kDa) are shown in ulcer tissues, while normal tissue contains trace amount of this growth factor.

Blotogram of plasminogen/angiostatin polypeptides is shown in Fig. 3. Although the marked immunoreactivity signal from the plasminogen band (~92 kDa) is detected in the samples of healthy tissue, the lack of its fragments is observed. However, significant amount of plasminogen degradation products, which may correspond to angiostatins K1-4.5 (~50 kDa) and K1-4 (40 kDa), along with their precursor protein are found in Martorell ulcer.

Gelatinases were identified by zymography, areas of MMP activities appear as clear zones against a dark blue background (Fig. 4). This method is able to detect MMPs even if they are still in the proenzyme form, because of removing preactivating peptide from the enzyme active center through disrupting interaction between Cys-73 and Zn²⁺ by SDS [13]. For all biopsy specimens taken from Mar-

torrell ulcer, a similar pattern of activated gelatinases was observed. The major gelatinases were MMP-9 (92 kDa), along with its 130 and 225 kDa dimer complexes, whereas both MMP-2 and its latent form were less expressed. In marked contrast, there was little gelatinase activity detected in the samples of healthy tissue. In this case, the MMP profile was represented by trace amount of MMP-9 and its high molecular weight dimers and proenzymes, while the rest of MMPs appeared to be undetectable. The above results of western blots and zymography were quantified by scanning densitometric data and the results are presented in Table 2.

It should be noted that tissue from non-healing Martorell HYTILU is characterized by dramatic VEGF overexpression (by 75 folds vs. normal tissue, *P* < 0.01) and up-regulation of angiostatin species K1-4.5 and K1-4, which are not detectable in the control samples. Activity of MMP-9 complex in ulcer tissue appeared to be 9 fold higher as compared

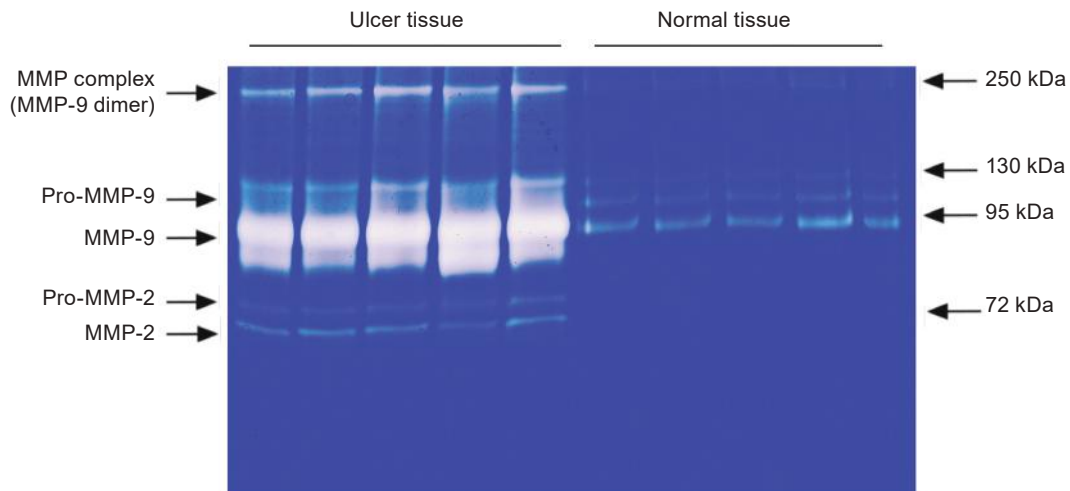


Fig. 4. Gelatin zymography of MMP activities in skin wound and healthy cutaneous bioplate specimens from the patient with Martorell ulcer

Table 2. Quantitative analysis of angiogenic regulator levels and MMP profile (in arbitrary units of optic density, Mean \pm SEM)

Parameter	Control tissue	Ulcer tissue
Total VEGF level	0.78 \pm 0.39	58.30 \pm 9.79*
Angiostatin K1-4.5 level	n/d	45.10 \pm 5.45
Angiostatin K1-4 level	n/d	16.10 \pm 0.68
MMP-complex	6.60 \pm 2.13	61.10 \pm 5.12*
MMP-9 activity	50.3 \pm 5.92	484.90 \pm 61.02*
MMP-2 activity	n/d	27.30 \pm 2.61

Notes: a.u. – arbitrary units, n/d – non determined. * $P < 0.01$ vs. parameter in normal tissue, $n = 5$, U Mann-Whitney test

with healthy control ($P < 0.01$) that corresponds 10-fold elevation of MMP-9 activity in the non-healing wound. In contrast with ulcer samples, no active MMP-2 gelatinase activity was detected in normal tissue. These results indicate a general correlation between angiostatin levels and activity of angiostatin-producing proteinases, MMPs.

Chronic wounds, including diabetic foot ulcers, venous leg ulcers and pressure ulcers, do not adhere to the standard time course of cellular and molecular events that lead towards healing of healthy acute wounds. Martorell HYTILU represents rapidly progressive and extremely painful ulcers that are frequently underdiagnosed, being a great clinical, therapeutic and biomedical challenge [1-3, 14]. The molecular basis of Martorell ulcers is generally unknown. However, currently, we were able to obtain tissue samples from non-diabetic patient suffering from chronic (2 years) Martorell ulcer of lower limb, developed due to the poor-controlled hypertension. In this study, we report for the first time results indicating elevation of MMP activation cascade and over-production of angiogenesis regulatory proteins (VEGF and angiostatins) in non-healing Martorell HYTILU.

It is known that angiogenesis is disturbed in abnormally healing wounds, and insufficient angiogenesis contributes to impaired wound healing and skin ulceration. Restoration of blood flow by neovascularization would help transport oxygen and nutrients to promote wound healing [15]. Hence, we focused our prime attention on the levels of

two major counteracting angiogenic regulators, VEGF and angiostatins. VEGF is considered to be the most potent proangiogenic growth factor in skin. The role and mechanisms of action of VEGF during wound healing, including its mitogenic and angiogenic action on the endothelial cells, have been widely studied [9, 16]. Healthy cutaneous tissue contains small amounts of VEGF, which are enough for maintaining normal endotheliocyte function. Up-regulation of VEGF occurs in response to local ischemic injury as a compensatory reaction in order to restore blood supply and is essential for proper wound healing [17]. Elevation of growth factor level in the studied patient's ulcer tissue means that chronic skin ulceration triggers ischemia-induced VEGF expression, however, the clinical significance of such pro-angiogenic response was not established. Earlier report indicates that chronic leg ulcer exudates inhibit endothelial cell proliferation and tube formation [18]. Other papers confirm that blocking angiogenesis significantly delays wound repair. For example, study of Drinkwater et al. [10] and later report of Smith and Hoffman [19] demonstrate that angiostatins may contribute to insufficient wound neovascularization even in the presence of elevated levels of VEGF and other growth factors. It can be explained by the fact that angiostatins exhibit potent antagonizing action toward VEGF, resulting in mitochondrial damage and activating apoptotic signaling pathway in endothelial cells [20]. Moreover, angiostatin proteins have been shown to inhibit neutrophil activation, induce apoptosis and block neutrophil recruitment [21]. Meanwhile, neutrophils are known to be the predominant cell type in the early inflammation phase and play very important role in wound healing by regulating inflammation, debridement of necrotic tissue, phagocytosis of infectious agents and producing various mediators and growth factors [22]. Recently, Ebaid [23] has shown that neutrophil depletion delayed cutaneous wound healing in rats through reduced proliferation and epidermal migration of the keratinocytes and the collagen deposition. Brubaker et al. [24] have reported that reduced neutrophil chemotaxis and infiltration contribute to delayed resolution of cutaneous wound infection in advanced age, which may be essentially critical for patients with Martorell HYTILU. Therefore, angiostatin-induced shortage of functional longevity of neutrophils, inhibition of their activation and recruitment can eventually prevent wound from healing. Based on these observations, we hypothesize that

the appearance and accumulation of angiostatin-like polypeptides in chronic Martorell ulcer may negatively affect healing in Martorell HYTILU patient. We detected two major discrete angiostatin isoforms, which migrated in electrophoresis as 50 kDa and 40 kDa plasminogen fragments, corresponding to K1-4.5 and K1-4 angiostatins, respectively. It is of interest that the first angiostatin-like polypeptide can be a product of plasmin auto-proteolysis, whereas the second one can be a result of MMP-mediated plasminogen fragmentation [25]. We were unable to measure plasmin activity in the studied samples due to the presence of serine protease inhibitors in the lysis buffer, so its contribution to angiostatin formation should be tested.

Remodeling extracellular matrix is a central aspect during normal wound healing. Gelatinases, namely MMP-2, which is produced by fibroblasts, osteoblasts, endothelial cells and macrophages, and MMP-9 observed in polymorphonuclear leukocytes, vascular pericytes, macrophages and keratinocytes, play crucial role in degradation of extracellular proteins. MMP activities facilitate the migration of cells, the deposition of new extracellular matrix, and the development of new tissue [4, 5]. Dysregulation of MMP activity may serve as a poor prognosis for wound healing and closure. Ladwig et al. [26] have shown that high levels of MMP-9 activity impair wound healing in chronic pressure ulcers and can be utilized as a predictor of healing efficiency in such type of ulcers. Persistent presence of gelatinases, plasmin and some other active proteinases results in degradation of extracellular matrix proteins, adhesion molecules, growth factors (VEGF, epidermal growth factor – EGF) and their receptors. Proteolytically derived angiogenesis inhibitors (angiostatins, endostatin), in turn, significantly contribute to failed healing of chronic wounds [27]. We demonstrate dramatic overactivation of gelatinases, first of all, MMP-9, in biopsy specimens taken from wound bed of Martorell ulcer patient. Together with the intense activation of other metalloproteinases and their complexes, they undoubtedly play a role in determining the chronicity of this wound.

In conclusion, hypertensive leg ulcers, known as Martorell syndrome, often fail to heal, however the molecular mechanisms of non-healing are not well explained. Until recently, there have been no studies evaluating levels of angiogenic regulators and MMP activities in non-healing wounds in Martorell HYTILU. In the present case report, we found

increased levels of angiostatic proteins and overactivation of gelatinases, which altogether can contribute to failed wound healing in patient, who suffers from Martorell ulcer as a consequence of poorly controlled hypertension. Testing angiogenic regulator profile and proteolytic activity in complex with comprehensive clinical history may help to choose specific and proper protocol for Martorell HYTILU management, which can include surgical or vacuum-assisted debridement and using of proteinase's inhibitors. For example, evaluation of MMP activities may be recommended to select the right strategy of surgical and dermaplastic intervention during ulcerization, because high MMP levels can cause dermal graft failure [28]. It would be advisable to perform more comprehensive investigations of such rare ulcerations involving large scale studies on underlying triggers and key molecular events. In order to aid advancement of wound healing research in directions that will lead to benefits in the clinic, a further dialogue between clinicians and basic scientists is desirable.

Conflict of interest. Authors have completed the Unified Conflicts of Interest form at http://ukrbiochemjournal.org/wp-content/uploads/2018/12/coi_disclosure.pdf and declare no conflict of interest.

ВМІСТ РЕГУЛЯТОРІВ АНГІОГЕНЕЗУ ТА АКТИВНІСТЬ ММР-2, -9 У ПАЦІЄНТА З ВИРАЗКОЮ МАРТОРЕЛЛА

O. M. Петренко¹, A. O. Тихомиров²✉

¹Національний медичний університет імені О. О. Богомольця, Київ, Україна;

²Інститут біохімії ім. О. В. Палладіна НАН України, Київ;

✉e-mail: artem_tykhomyrov@ukr.net

Ішемічні виразки шкіри ніг хворих на гіпертонічну хворобу (синдром Марторелла) є незвичайною формою хронічних виразок нижніх кінцівок, які виникають на фоні неконтрольованого високого кров'яного тиску. Метою роботи було дослідити вміст протеїнів-регуляторів ангіогенезу (фактора росту ендотеліоцитів судин, або VEGF, та ангіостатинів), а також визначити активність матриксних металопротеїназ (ММР) (желатиназ ММР-2 та -9) у пошкодженій тканині шкіри пацієнта з дворічною історією

розвитку виразки Марторелла. Рівні VEGF та ангіостатинів визначали за допомогою імуноблотингу, активність MMP аналізували з використанням желатинової зимографії. Вперше показано, що тканини виразки за синдрому Марторелла характеризуються підвищеним вмістом VEGF (у 75 разів у порівнянні з гістологічно нормальними біоптатами, $P < 0,01$) та підсиленою продукцією ангіостатинів, які не виявляються у здоровій тканині. Приблизно 10-разове зростання активності MMP-2 та -9 спостерігається у тканині виразки порівняно з неураженою тканиною шкіри. Одержані результати свідчать, що підвищена продукція ангіостатинів може інгібувати проангіогенні ефекти VEGF і, разом із надактивацією MMP, сприяти хронізації ішемічної виразки. Подальшого з'ясування потребують питання, пов'язані з використанням визначення змін профілю регуляторів ангіогенезу та активності протеолітичних систем у клінічній практиці з метою вибору адекватної стратегії лікування хворих із виразкою Марторелла, зокрема хірургічного очищення рани та/або пересадки шкіри.

Ключові слова: виразка Марторелла, хронічні рани, регулятори ангіогенезу, VEGF, ангіостатини, MMP.

References

1. Conde Montero E, Guisado Muñoz S, Pérez Jerónimo L, Peral Vazquez A, Montoro Lopez JJ, Hocajada Reales C, Baniandrés Rodriguez O, de la Cueva Dobao P. Martorell hypertensive ischemic ulcer successfully treated with punch skin grafting. *Wounds*. 2018; 30(2): E9-E12.
2. Hafner J, Nobbe S, Partsch H, Läubli S, Mayer D, Amann-Vesti B, Speich R, Schmid C, Burg G, French LE. Martorell hypertensive ischemic leg ulcer: a model of ischemic subcutaneous arteriolosclerosis. *Arch Dermatol*. 2010; 146(9): 961-968.
3. Malhi HK, Didan A, Ponosh S, Kumarasinghe SP. Painful leg ulceration in a poorly controlled hypertensive patient: a case report of Martorell ulcer. *Case Rep Dermatol*. 2017; 9(1): 95-102.
4. Rohani MG, Parks WC. Matrix remodeling by MMPs during wound repair. *Matrix Biol*. 2015; 44-46: 113-121.
5. Lazaro JL, Izzo V, Meaume S, Davies AH, Lobmann R, Uccioli L. Elevated levels of matrix metalloproteinases and chronic wound healing: an updated review of clinical evidence. *J Wound Care*. 2016; 25(5): 277-287.
6. Cornelius LA, Nehring LC, Harding E, Bolanowski M, Welgus HG, Kobayashi DK, Pierce RA, Shapiro SD. Matrix metalloproteinases generate angiostatin: effects on neovascularization. *J Immunol*. 1998; 161(12): 6845-6852.
7. Hatziapostolou M, Katsoris P, Papadimitriou E. Different inhibitors of plasmin differentially affect angiostatin production and angiogenesis. *Eur J Pharmacol*. 2003; 460(1): 1-8.
8. Hanford HA, Wong CA, Kassan H, Cundiff DL, Chandel N, Underwood S, Mitchell CA, Soff GA. Angiostatin(4.5)-mediated apoptosis of vascular endothelial cells. *Cancer Res*. 2003; 63(14): 4275-4280.
9. Johnson KE, Wilgus TA. Vascular endothelial growth factor and angiogenesis in the regulation of cutaneous wound repair. *Adv Wound Care*. 2014; 3(10): 647-661.
10. Drinkwater SL, Burnand KG, Ding R, Smith A. Increased but ineffectual angiogenic drive in nonhealing venous leg ulcers. *J Vasc Surg*. 2003; 38(5): 1106-1112.
11. Stoscheck CM. Quantitation of protein. *Methods Enzymol*. 1990; 182: 50-68.
12. Tykomyrov AA, Yusova EI, Diordieva SI, Corsa VV, Grinenko TV. Production and characteristics of antibodies against K1-3 fragment of human plasminogen. *Biotechnol Acta*. 2013; 6(1): 86-96.
13. Snoek-van Beurden PA, Von den Hoff JW. Zymographic techniques for the analysis of matrix metalloproteinases and their inhibitors. *Biotechniques*. 2005; 38(1): 73-83.
14. Alavi A, Mayer D, Hafner J, Sibbald RG. Martorell hypertensive ischemic leg ulcer: an underdiagnosed Entity©. *Adv Skin Wound Care*. 2012; 25(12): 563-572.
15. Demidova-Rice TN, Durham JT, Herman IM. Wound healing angiogenesis: innovations and challenges in acute and chronic wound healing. *Adv Wound Care*. 2012; 1(1): 17-22.
16. Eming SA, Krieg T. Molecular mechanisms of VEGF-A action during tissue repair. *J Investig Dermatol Symp Proc*. 2006; 11(1): 79-86.
17. Zhang F, Lei MP, Oswald TM, Pang Y, Blain B, Cai ZW, Lineaweaver WC. The effect of vascular endothelial growth factor on the healing of

- ischaemic skin wounds. *Br J Plast Surg*. 2003; 56(4): 334-341.
18. Drinkwater SL, Smith A, Sawyer BM, Burnand KG. Effect of venous ulcer exudates on angiogenesis *in vitro*. *Br J Surg*. 2002; 89(6): 709-713.
 19. Smith E, Hoffman R. Multiple fragments related to angiostatin and endostatin in fluid from venous leg ulcers. *Wound Repair Regen*. 2005; 13(2): 148-157.
 20. Chen YH, Wu HL, Chen CK, Huang YH, Yang BC, Wu LW. Angiostatin antagonizes the action of VEGF-A in human endothelial cells via two distinct pathways. *Biochem Biophys Res Commun*. 2003; 310(3): 804-810.
 21. Aulakh GK, Balachandran Y, Liu L, Singh B. Angiostatin inhibits activation and migration of neutrophils. *Cell Tissue Res*. 2014; 355(2): 375-396.
 22. Wilgus TA, Roy S, McDaniel JC. Neutrophils and wound repair: positive actions and negative reactions. *Adv Wound Care*. 2013; 2(7): 379-388.
 23. Ebaid H. Neutrophil depletion in the early inflammatory phase delayed cutaneous wound healing in older rats: improvements due to the use of un-denatured camel whey protein. *Diagn Pathol*. 2014; 9: 46.
 24. Brubaker AL, Rendon JL, Ramirez L, Choudhry MA, Kovacs EJ. Reduced neutrophil chemotaxis and infiltration contributes to delayed resolution of cutaneous wound infection with advanced age. *J Immunol*. 2013; 190(4): 1746-1757.
 25. Doll JA, Soff GA. Angiostatin. *Cancer Treat Res*. 2005; 126: 175-204.
 26. Ladwig GP, Robson MC, Liu R, Kuhn MA, Muir DF, Schultz GS. Ratios of activated matrix metalloproteinase-9 to tissue inhibitor of matrix metalloproteinase-1 in wound fluids are inversely correlated with healing of pressure ulcers. *Wound Repair Regen*. 2002; 10(1): 26-37.
 27. Lauer G, Sollberg S, Cole M, Flamme I, Stürzebecher J, Mann K, Krieg T, Eming SA. Expression and proteolysis of vascular endothelial growth factor is increased in chronic wounds. *J Invest Dermatol*. 2000; 115(1): 12-18.
 28. Izzo V, Meloni M, Vainieri E, Giurato L, Ruotolo V, Uccioli L. High matrix metalloproteinase levels are associated with dermal graft failure in diabetic foot ulcers. *Int J Low Extrem Wounds*. 2014; 13(3): 191-196.