



## CRANIOLOGICAL FEATURES OF THE AMERICAN MINK IN SOUTH-EASTERN BELARUS

Alexandr Savarin 

### Key words

Belarus, *Neovison vison*, skull, pathology, abnormal number of teeth, viability

### doi

<http://doi.org/10.53452/TU2609>

### Article info

submitted 20.11.2023  
revised 10.12.2023  
accepted 30.12.2023

### Language

English, Ukrainian summary

### Affiliations

Gomel F. Skorina State University (Gomel, Belarus)

### Correspondence

A. A. Savarin; 3a Pavlov Street, Gomel, 246026 Belarus; Email: [gomelsavarin@gmail.com](mailto:gomelsavarin@gmail.com); orcid: 0000-0001-9663-6115

### Abstract

A series of skulls ( $n = 27$ ) of the American mink (*Neogale vison*) from the south-east of Belarus (Gomel region, floodplain of the Sozh River) was studied. The animals were caught by different hunters in 2000–2004. The sex of individuals was not determined. When examining the skull, only the most pronounced morpho-anatomical changes that can be diagnosed confidently as deviations from the norm were taken into account. In all cases, lamellar deposition of calcium salts in the area of *tentorium cerebelli osseum* inside the cranial vault was detected. The growing plate length reached half of the arch height in some individuals. These traits (considerable area of bone plates; presence of a sharp spine growing in different plains) allow suggesting that the analysed growths are of pathological origin. This pathology can considerably affect the viability and physiological status of individuals as it disrupts the functioning of the central nervous system. It is difficult to identify the cause of intracranial calcifications due to the possible effect of factors of various nature. Some degree of calcification of the opisthion region of *foramen magnum* was found. The changes occurred in the foramen shape cannot be considered phenetic variability. In most individuals, the thinning of maxillary bone in the teeth roots area is observed. However, we believe that the identified degree of bone tissue thinning is not critical and therefore does not affect the life expectancy of individuals. Two adult individuals have swelling of the maxillary bone. In one case, an extensive bone tissue excavation was identified on the left lower jaw, which led to the loss of the canine tooth. The analysed pathomorphological change is not of traumatic nature because in case of post-traumatic osteomyelitis sequesters (separating fragments) are formed. It is necessary to further analyse the American mink skulls available at scientific collections of Belarus and to identify the degree of calcium salt deposits and their impact on the *foramen magnum* phenotypes. We consider it necessary to create an annotated catalogue of pathologies and anomalies of the skull of the American mink in the south-east of Belarus and adjacent territories of Ukraine, since the morphological method is essential in the diagnosis of bone tissue diseases.

### Cite as

Savarin, A. 2023. Craniological features of the American mink (*Neogale vison*) in south-eastern Belarus. *Theriologia Ukrainica*, **26**: 87–95. [In English, with Ukrainian summary]

## Краніологічні особливості візона річкового (*Neogale vison*) на південному сході Білорусі

Аляксандр Саварин

**Резюме.** Досліджено серію черепів ( $n = 27$ ) візона річкового (*Neogale vison*), що мешкає на південному сході Білорусі (Гомельський район, заплава р. Сож). Тварин здобуто різними мисливцями протягом 2000–2004 рр. Стать особин не визначали. Під час огляду черепа враховували лише найбільш яскраво виражені морфо-анатомічні зміни, які можна діагностувати як відхилення від «норми». У всіх випадках виявлено пластинчасте відкладення солей кальцію всередині склепіння черепа в області *tentorium cerebelli osseum*. Довжина ростучої пластини в окремих особин досягала половини висоти склепіння. Виявлені факти (значна площа кісткових пластин, що утворилися; наявність гострого шипа, що росте в різних площинах) дають підстави вважати, що аналізовані утворення мають патологічне походження. Ця патологія може істотно впливати на життєздатність особин, їхній фізіологічний статус, оскільки порушує роботу центральної нервової системи. Виявити причину утворення внутрішньочерепних кальцинатів важко з огляду на можливий вплив багатьох факторів різної природи. Виявлено в різному ступені виразності кальцинування ділянки опістона потиличного отвору. Зміни форми черепа в області *tentorium cerebelli osseum* при цьому, не можна вважати тільки фенетичною мінливістю. У більшості особин спостерігається стоншення верхньощелепної кістки в ділянці коренів зубів. Однак, вважаємо, що виявлений ступінь стоншення тканини не є критичним, тому й не може впливати на тривалість життя особин. У двох дорослих особин виявлено здуття верхньощелепної кістки. В одному випадку на лівому боці нижньої щелепи виявлено велику виїмку кісткової тканини, що призвела до втрати ікла. Аналізована патоморфологічна зміна не має травматичної природи, оскільки в разі посттравматичного остеомієліту утворюються секвестри (відокремлені фрагменти). Необхідно проаналізувати наявний у Білорусі колекційний фонд черепів візона річкового, виявити ступінь відкладення солей кальцію та їхнього впливу на фенотипи великого потиличного отвору. Вважаємо за необхідне створити анотований каталог патологій і аномалій черепа *Neogale vison*, що мешкає на південному сході Білорусі та прилеглих територіях України, тому що морфологічний метод є основним у діагностиці захворювань кісткової тканини.

**Ключові слова:** Білорусь, *Neovison vison*, череп, патологія, життєздатність.

### Introduction

The American mink (*Neovison vison*) is a widely distributed, abundant invasive species of predatory mammals in Belarus. In 2022, the population of this unregulated game species was about 24 500 individuals [Hunting 2022]. The formation of geographic populations of the American mink in Belarus was influenced by the following factors: introduction in the mid-20th century, migration of feral populations from neighbouring countries, and escape of animals from fur farms. However, individuals that escaped from fur farms into the wild do not constitute the core of the wild population in the Gomel region [Valnistry *et al.* 2020].

This predator significantly affects the diversity and stability of various zoocoenoses [Zschille *et al.* 2004; Roy *et al.* 2009]. Therefore, analysing the viability of American mink populations is of interest not only in theoretical but also in practical terms. A series of publications on the morphology and ecology of the American mink in Belarus covered the metric and phenetic characteristics of the skull [Kruska & Sidorovich 2003; Ulevičius *et al.* 2001], reproductive plasticity [Sidorovich 1993], trophic links, and a range of other issues [Sidorovich 1997]. However, there is a lack of works analysing the pathoanatomical features of the skull of the American mink residing in Belarus and assessing their impact on the viability of individuals. This circumstance indicates the relevance and novelty of the obtained results.

Research on skull pathologies caused by parasitism of nasal nematodes of the genus *Skrjabinogylus* has been conducted. In the geographic populations of American minks, these parasites were found in more than 50% of individuals [Tumlison & Tumlison 2019]. With a high degree of invasion, swellings of the bones (especially the frontal bones), perforation, and alteration of the bone

tissue structure are observed in the facial and cerebral parts of the skull. However, some experts believe that the parasite is not a significant mortality factor for mustelids, capable of affecting population reduction [Heddergott *et al.* 2016; Frantz *et al.* 2022].

A publication by Lithuanian veterinarians on the prevalence of dental and jaw pathologies in free-living minks (sample size statistically significant,  $n = 93$ ) is of interest [Stavrou 2021]. The analysis included stages of periodontal disease and bone defects. Periodontal diseases were found in 55% and changes in pulp colour and tooth necrosis in 77% of skulls. Unfortunately, analysing the pathomorphological changes of the skull vault was not part of this study.

The course of pathophysiological processes in wild animals is chronic and caused by various factors (genetic, traumatic, teratogenic, etc.). It should be emphasised that in mammalogy, unified criteria for evaluating various morpho-anatomical changes have not been developed.

## Materials and Methods

A collection of American mink skulls ( $n = 27$ ) was analysed, obtained from individuals hunted by various hunters between 2000 and 2004 in the Gomel region, specifically in the floodplains of the Sozh River. This sample is one of the most numerous available in Belarus. For comparison, Ulevičius *et al.* [2001] obtained samples from 15 geographic populations of American minks across the country, of which only 4 were more numerous (ranging from 42 to 75 individuals).

The sex of the minks hunted in the Gomel region was not identified by the hunters. The age of the individuals was determined by a set of characteristics: measurements of the skull (primarily the condylobasal length), the prominence of skull ridges and sutures, and the degree of tooth wear.

During the skull examination, only the most pronounced morpho-anatomical changes were considered, which were preliminarily assessed as potential deviations from the 'norm'. To evaluate the degree of calcium salt deposits, five skulls were cut transversely.

The primary goal of the study was a *preliminary assessment* of the impact of identified skull changes on the viability of individuals. Since it is not feasible to determine the full extent of the impact of these changes on the physiological status of the individuals based solely on morpho-anatomical analysis (without cytological, biochemical, hematological, etc. studies), this goal is methodologically justified. Furthermore, the morphological method is fundamental in diagnosing bone tissue diseases.

## Results and Discussion

### *Calcium salt deposition*

It is known that in the occipital part of the skull of some mammals (carnivores, primates, marsupials, certain cetaceans), a bony tentorium cerebelli (*tentorium cerebelli osseum*) forms—a normal structure located at the boundary between the cerebellum and the cerebral hemispheres [Atlas... 2004]. This bony tentorium is situated laterally from the internal occipital protuberance (*protuberantia occipitalis interna*) and extends to the posterior edges of the parietal bone, resembling a bone 'leaflet' [Mead & Fordyce 2009]. Some authors attribute phylogenetic significance to this structure, as well as to other morpho-anatomical features of the endocranium [Diaz-Berenguer *et al.* 2021]. Studies have analysed the location [Czubaj *et al.* 2015] and thickness of the *t. c. osseum* in various pathophysiological processes [Hartley *et al.* 2005; Wahl *et al.* 2020]. For instance, thickening of the *t. c. osseum* due to hypovitaminosis A has been identified in African lions (*Panthera leo*) [Hartley *et al.* 2005]. However, the variability of the bony tentorium is poorly studied, even in domestic animals, let alone in wild species.

The most characteristic feature of the skull of the American mink residing in the south-east of Belarus is the lamellar deposition of calcium salts on the vault, particularly around the bony tentorium. This was found in all skulls ( $n = 27$ ), including young individuals (yearlings caught in October–November, condylobasal length 58–59 mm).

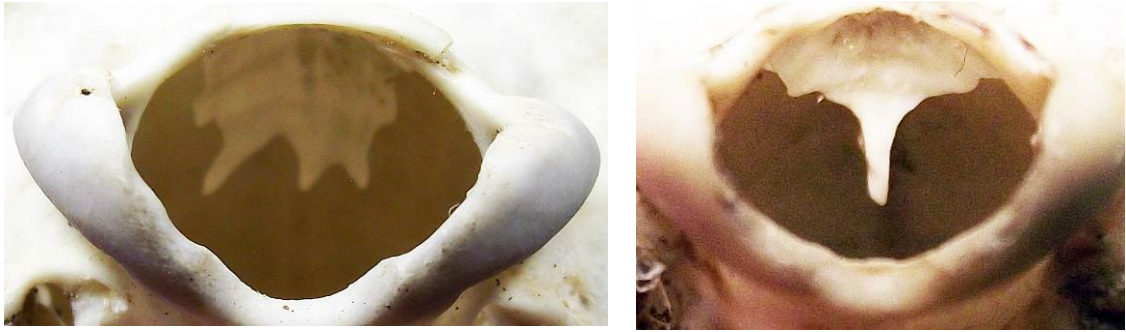

Fig. 1. The serrated shape of the salt plates (view through the *foramen magnum*).

Рис. 1. Зубчата форма сольової пластини (вид через потиличний отвір).

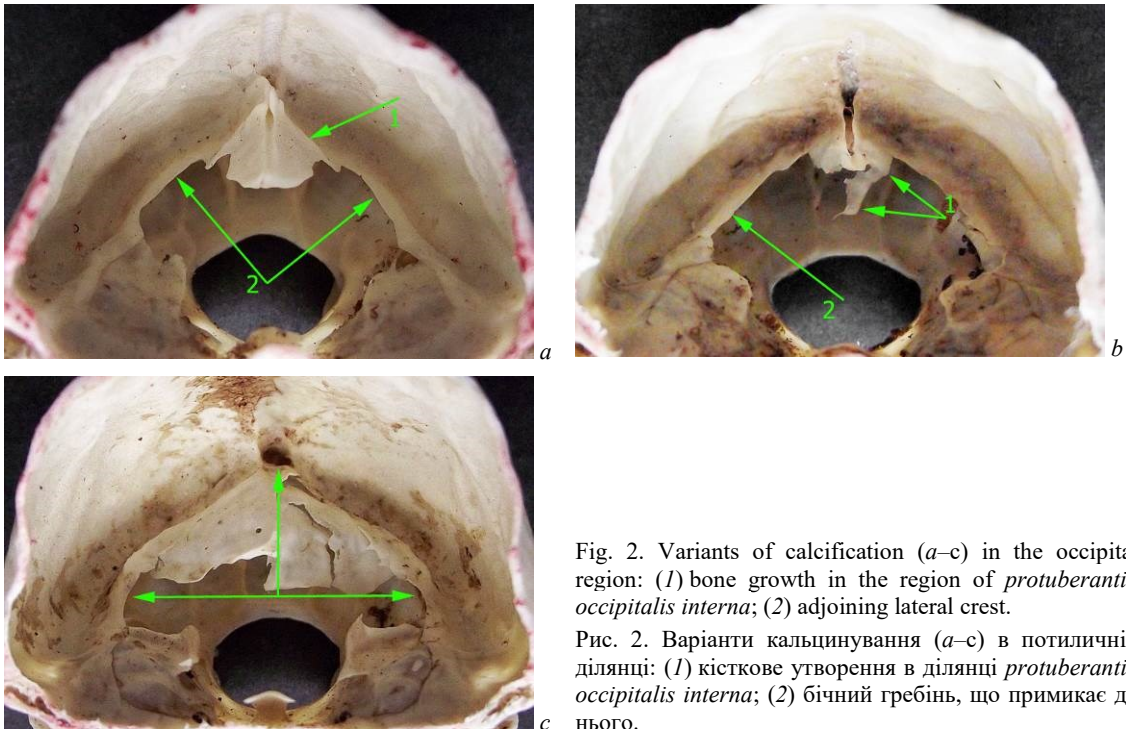


Fig. 2. Variants of calcification (a–c) in the occipital region: (1) bone growth in the region of *protuberantia occipitalis interna*; (2) adjoining lateral crest.

Рис. 2. Варіанти кальцинування (a–c) в потиличній ділянці: (1) кісткове утворення в ділянці *protuberantia occipitalis interna*; (2) бічний гребінь, що примикає до нього.

The colour of these deposits does not differ from the bone tissue of the skull vault. The shape of the growing plate is quite variable—from serrated to round, or of an indeterminate form (Fig. 1, 2). The length of this plate can be up to half the height of the skull vault. There are reasons to believe that pathophysiological processes also influence the formation of this bone structure, namely:

- In some cases, the growth of bone tissue is accompanied by the formation of a long sharp spike (Fig. 1 right, Fig. 2 b). This spike can grow in various planes (about a 90-degree gradient).
- Adjacent to this bone formation around the internal occipital protuberance (Fig. 2, 1) are bone ridges on both sides of the skull (Fig. 2, 2). In one case, complete fusion (union) of the lateral ridges was found (Fig. 2, c), forming a plate almost in the shape of a semicircle (about 180 degrees).

The causes of calcium salt deposits are diverse—parasitic diseases, endocrine and metabolic disorders caused by the aging process, and others [Kiroğlu *et al.* 2010]. Massive calcifications compress the brain, disrupt cerebrospinal fluid circulation, and, consequently, lead to the malfunctioning of the central nervous system and other systems, accordingly. We suggest that the analysed bone

formations should be considered a pathology that can significantly affect the physiological state and viability of American mink individuals.

The shape of the *foramen magnum* in American minks is variable, as in other mammalian species, and is considered one of the phenetic characteristics of the skull. For example, Ulevičius *et al.* [2001], in their examination of mink skulls from Belarus, identified three variants: round, pyramidal, and pear-shaped. The occipital tubercles (*tubercula nuchalia*) somewhat influence the shape of the large foramen.

It should be noted that calcium salts can theoretically deposit in any part of the skeleton in all mammalian species, and the issue of pathophysiological deposition of salts around the foramen magnum in wild species is virtually unexplored.

In analysing the morphology of the foramen magnum of American mink skulls from south-east Belarus, the following features were identified:

- The upper edge can be smooth (Fig. 3, *a*), or have pronounced elevations (tubercles) on the left or right, or simultaneously on both sides of the opisthion (Fig. 3, *b–c*) (63% of the sample). Interestingly, both forms are observed in individuals of different ages. Thus, *the presence of occipital tubercles is not solely a morphological manifestation of maturation, indicating that various factors influence the formation of these tubercles.*
- In two individuals with pronounced tubercles on the outer surface, the formation of sharp spikes was also found on the inner surface (Fig. 3, *d*).

Fig. 3 shows the maximum degree of tubercle prominence in the sample skulls. Such a form of the upper edge of the foramen magnum cannot be merely a variation, as the ‘serration’ of the opening can affect the mobility of the first cervical vertebra (atlas). The presence of sharp points inside (Fig. 3, *d*) confirms the emergence of new calcification sites. Various factors influencing the formation of tubercles support the viewpoint of presumed calcification in some skulls. However, to determine the extent to which pathophysiological processes influence the formation of tubercles on the upper edge of the large foramen, it is necessary to analyse the entire collection of American mink skulls in Belarus (and feasibly the adjacent northern territories of Ukraine), paying particular attention to the frequency of this feature in yearlings and adults.

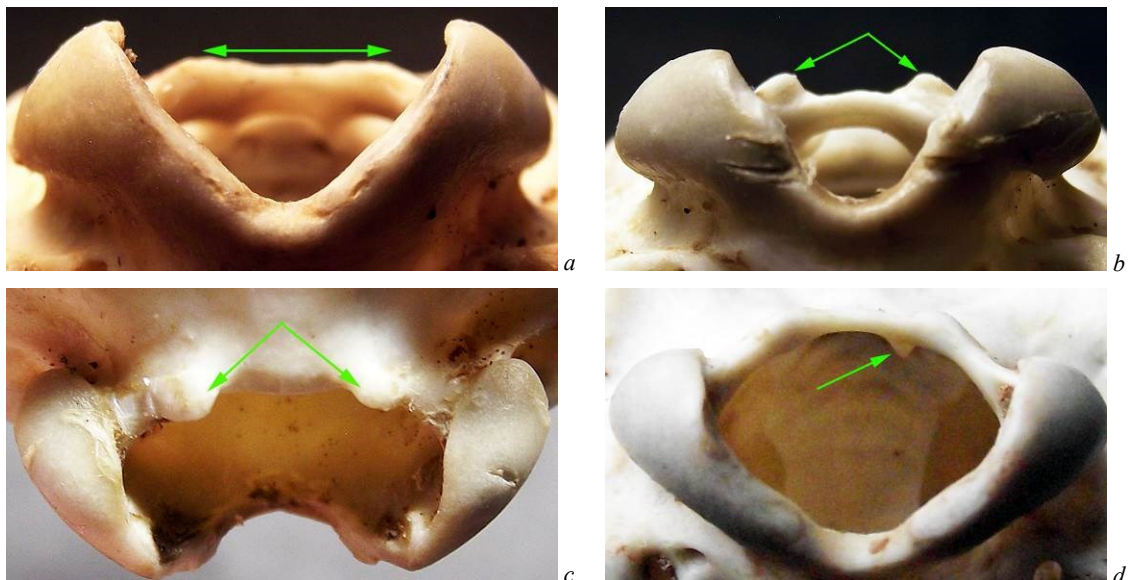


Fig. 3. The upper edge of the *foramen magnum*: (*a*) smooth; (*b*, *c*) with tubercles; (*d*) spike (from inside).

Рис. 3. Верхній край потиличного отвору: (*a*) гладкий, (*b*, *c*) з горбками, (*d*) шип (зсередини).

Considering the calcification on both sides of the skull, it can be assumed that the disturbance in calcium salt metabolism in the local population of American minks is systemic.

#### ***Thinning of the bone tissue of the upper jaw around the tooth roots***

Periodontal diseases are widespread among predatory wild and domestic mammalian species [Hungerford *et al.* 1999; Niemiec 2013]. Periodontitis is a chronic disease that intensifies with age [Hendy *et al.* 2022], leading to osteoclastic bone resorption (osteolysis, bone destruction) in its late stages [Oz & Puleo, 2011]. The main manifestations of periodontitis include increased tooth mobility, gingival enlargement or recession (thinning with the descent of the gingival margin and exposure of tooth roots), resorption, and thinning of the bone. Periodontal diseases have a multifactorial nature [Asquino *et al.* 2022], but bacteria in dental plaque play a triggering role in their onset [Niemiec 2013].

In American minks from south-east Belarus, bone tissue thinning manifests as ‘sagging’ of the bone tissue with exposure of tooth roots. The maxillary bone acquires a fine-celled, porous structure (Fig. 4), facilitating the penetration of pathogenic microorganisms.

It should be clarified that the surface of the maxillary bone normally has a small number of openings for blood vessels and nerves (*foramina alveolaria*) (Fig. 4 *a*, 1). Impressions of some vessels are noticeable on the bone tissue (Fig. 4 *a*, 2). However, in most cases, the number of these openings is in the dozens (Fig. 4 *b*, *c*), and their diameter is noticeably expanded. As their number increases, the tuberosity of the bone tissue also increases. On the hard palate, between the third premolar and the molar, a significant sagging of the bone tissue with many perforations is clearly visible (Fig. 4 *d*). A similar pathology was also found in minks from Lithuania [Stavrou 2021] (according to veterinarians, the analysed changes in bone tissue represent stage 3 periodontosis).

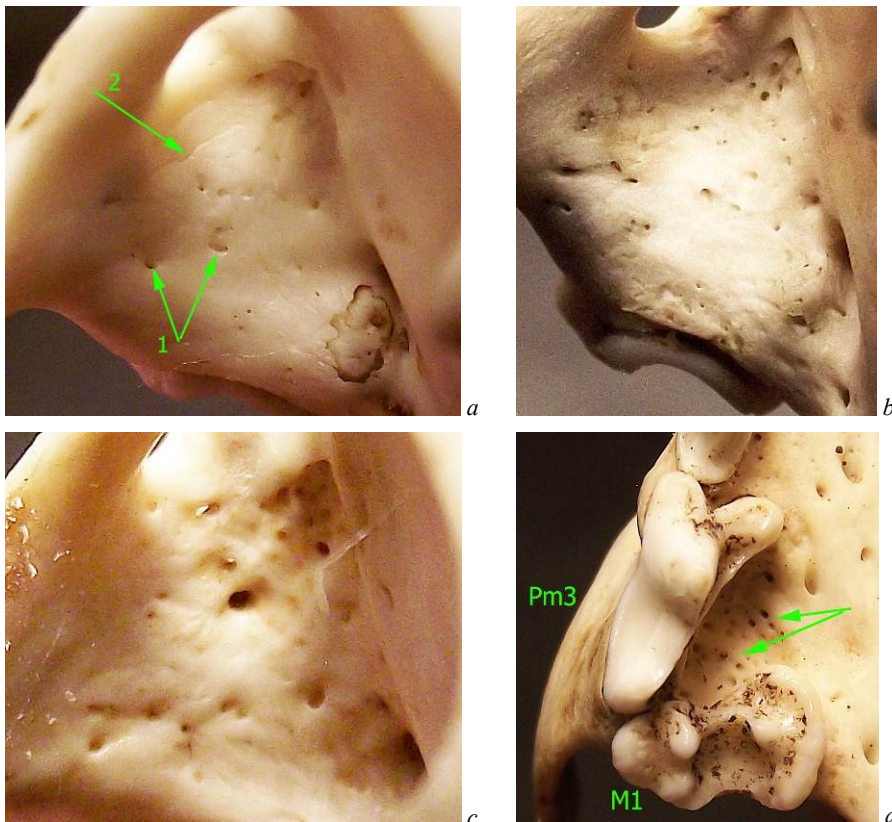


Fig. 4. Variants of perforation (*a–d*) of the maxillary bones: (1) openings; (2) imprints of blood vessels.

Рис. 4. Варіанти перфорованості (*a–d*) верхньощелепної кістки: (1) отвори, (2) відбитки кровеносних судин.

In American minks from south-east Belarus, thinning of the maxillary bone around tooth roots is observed in 92.6% of cases, consistent with the results of studies of minks from Lithuania.

Thinning leads to a decrease in the mechanical strength of the upper jaw and loosening of the teeth. However, it is believed that the identified degree of thinning is not critical and therefore does not affect the lifespan of the individuals. Our opinion is also supported by the results of studies of similar pathologies in hedgehogs from the territory of Belarus [Savarin 2015].

### **Swelling of the maxillary bone**

In two cases among adult individuals (7.4% of the sample), a localised swelling (elevation) of the bone tissue was observed (Fig. 5, 3). The etiology of these formations cannot be clarified without cutting the jaw and studying the corresponding morpho-anatomical picture (this will be done in further research).

The diverse morpho-anatomical changes shown in Fig. 5 in one individual confirm the scientific fact: pathophysiological processes of various etiologies can simultaneously occur in the same section of bone tissue [Koval 1984].

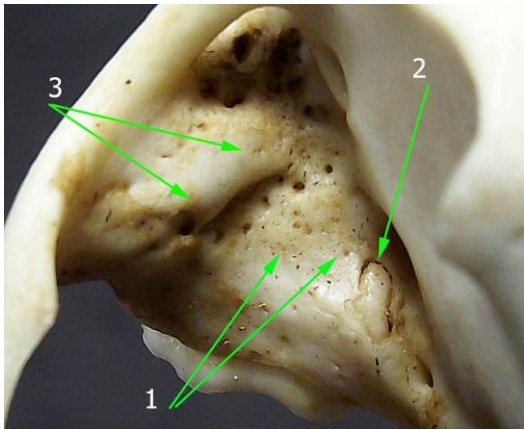


Fig. 5. Pathomorphological changes of the maxilla: (1) formation of small round perforations; (2) exposure of tooth roots; (3) swelling of bone tissue.

Рис. 5. Патоморфологічні зміни верхньощелепної кістки: (1) утворення дрібних округлих перфорацій, (2) оголення коренів зубів, (3) здуття кісткової тканини.

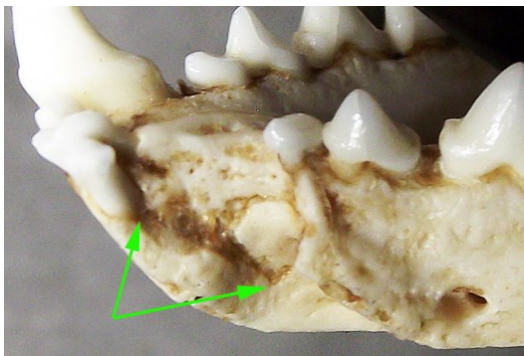


Fig. 6. Bone tissue damage with indentation in the lower jaw.

Рис. 6. Руйнування з виїмкою кісткової тканини нижньої щелепи.

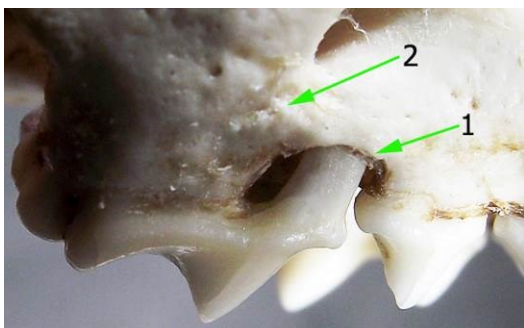


Fig. 7. Bone tissue damage in the upper jaw (the same individual): (1) exposure of tooth root; (2) coverage of adjacent tissue.

Рис. 7. Руйнування кісткової тканини верхньої щелепи (та сама особина): (1) оголення кореня зуба, (2) охоплення прилеглої тканини.

### ***Destruction of lower jawbone tissue with notching***

In one adult individual, on the left side of the lower jaw, a transverse notch of bone tissue with an average width of about 2.5 mm was found, leading to the complete loss of the canine tooth (Fig. 6). The bone areas adjacent to the notch were thickened. This pathomorphological change is not of traumatic origin, as post-traumatic osteomyelitis would result in sequestration (separating fragments). Such extensive pathology is found in individual cases among a wide range of mammals of different taxonomic and ecological groups in Belarus (weasels, shrews, moles, hedgehogs, mice, etc.) [Savarin 2015] and other regions.

On the right side of the upper jaw of the same individual, around the first molar tooth, there is a significant area of destruction (2 mm) involving the adjacent bone tissue (Fig. 7, 1–2 respectively). Such a change in the maxillary bone is a pathology observed in the skulls of many predators [Atchley *et al.* 2013; Jurgelėnas *et al.* 2023].

According to the literature, bone tissue destruction is typically caused by inflammatory bacterial diseases of the hard and soft tissues of the tooth and gum [Niemic 2013].

### **Conclusions**

In most cases, in the skulls of American minks caught in south-east Belarus from 2000 to 2004, deposits of calcium salts are found inside the skull around the bony tentorium (*tentorium cerebelli osseum*). The identified facts (significant area of formed bone plates; presence of a sharp spike growing in different planes) suggest that these formations have a pathological origin. Such voluminous salt deposits should disrupt the functioning of the central nervous system and thus significantly affect the viability of the individuals. Identifying the cause of intracranial calcifications is difficult due to the potential influence of many factors of different nature.

The presence of occipital tubercles (*tubercula nuchalia*) is not just a morphological manifestation of maturation, indicating that various factors influence their formation. The shape of the upper edge of the *foramen magnum* cannot be just a variation, as the ‘serration’ of the opening can affect the mobility of the first cervical vertebra. Therefore, it is advisable to analyse the collection of American mink skulls in Belarus to determine the degree of calcium salt deposits and their influence on the phenotypes of the large foramen, as well as possible blockage (*conrescentia vertebrarum*) of the first cervical vertebrae—fusion of several vertebrae due to calcium deposition.

Considering the calcification on both sides of the skull, it can be assumed that the disturbance in calcium salt metabolism in the local population of American minks is systemic.

Almost all individuals exhibit thinning of the maxillary bone around tooth roots to some degree. As a result, the maxillary bone acquires a fine-celled, porous structure. As their number increases, the tuberosity of the bone tissue also increases. It is believed that the identified degree of development of this pathophysiological process does not affect the lifespan of American minks.

The obtained research results are preliminary. It is considered necessary in further research to create an annotated catalogue of anomalies and pathologies of the skull of the American mink residing in south-east Belarus and adjacent territories of Ukraine, as the morphological method is fundamental in diagnosing bone tissue diseases. Such catalogues should contribute to the creation of unified methods for assessing certain morpho-anatomical changes in the skull, as well as help specialists from different regions to analyse their own collected craniological material. We believe that craniological monitoring requires the cooperation of a wide range of specialists (histologists, pathologists, microbiologists, helminthologists, etc.).

### **Acknowledgements**

This research received no specific funding from any public, commercial, or non-profit agency. We greatly appreciate the time and careful consideration received from reviewers and the subject editor.

The author is grateful to hunter S. A. Lipsky (Gomel, Belarus) for providing a large number of American mink skulls and Valeria Savarina for her help in translating the manuscript into English.



## References

- Asquino, N., G. Vigil, V. P. Prado, L. A. B. Rossy, R. B. Molina. 2022. Bone resorption in periodontal disease: the role of RANK, RANKL and OPG. A literature review. *Odontostomatologia*, **24**: 1–12. [CrossRef](#)
- Atchley, A. L., K. E. Carr, K. M. K. Luong, J. V. Evenhuis, F. J. M. Verstraete. 2023. Dental and temporomandibular joint pathology of the red fox (*Vulpes vulpes*). *Journal of Comparative Pathology*, **207**: 33–44. [CrossRef](#)
- Atlas...2004. *Atlas der Röntgenanatomie der Katze*. Parey Verlag, Stuttgart, 1–117.
- Czubay, N., M. Skibniewski, M. Kupczyńska, K. Barszcz, W. Sokolowski. 2015. Clinical anatomy of syringomyelia and Chiari malformation in dogs. *Med. Weter.*, **71** (3): 146–151.
- Diaz-Berenguer, E., M. Moreno-Azanza, A. Badiola, J. I. Canudo. 2021. The ossification of the falx cerebri in Sireniacans: evolution and phylogenetical signal. *9th International Meeting on the Secondary Adaptation of Tetrapods to Life in Water*. Chile, 34.
- Frantz, A. C., L. C. Salazar, F. Müller, P. Steinbach, J. Wittische, M. Heddergott. 2022. Interactions of cranial helminths in the European polecat (*Mustela putorius*): Implications for host body condition. *International Journal for Parasitology: Parasites and Wildlife*, **18**: 273–282. [CrossRef](#)
- Hartley, M. P., R. M. Kirberger, M. Haagenson, L. 2005. Sweets Diagnosis of hypovitaminosis A using magnetic resonance imaging in African lions (*Pantheraleo*). *Journal of the South African Veterinary Association*, **76** (3): 132–137. [CrossRef](#)
- Heddergott, M., D.Pohl, P. Steinbach, L. C. Salazar, F.Müller, A. C. Frantz. 2016. Determinants and effects of sinus worm *Skrjabinigylus nasicola* (Nematoda: Metastrongyloidea) infestation in invasive American mink *Neovison vison* in Germany. *Parasitology Research*, **115**: 3449–3457. [CrossRef](#)
- Hendy, E. A., F. D. Elseddawy, A. E. Behery, S. A. Ezzeldein. 2022. A Retrospective Study on Periodontal Diseases in Companion Animals. *Zagazig Veterinary Journal*, **50** (3): 255–263. [CrossRef](#)
- Hungerford, L. L., M. A. Mitchell, C. M. Nixon, T. E. Esker, J. B. Sullivan, R. Koerkenmeier, S. M. Marretta. 1999. Periodontal and dental lesions in raccoons from a farming and a recreational area in Illinois. *Journal of Wildlife Diseases*, **35** (4): 728–734. [CrossRef](#)
- Hunting... 2022. *Hunting Management Report for 2022*. Ministry of Forestry of the Republic of Belarus, Minsk, 1–6. [In Russian]
- Jurgelėnas, E., I. Jasinevičiūtė, L. Daugnora. 2023. Prevalence and Characterization of Dental and Skull-Bone Pathologies of the Raccoon Dog (*Nyctereutes procyonoides*) in Lithuania. *Animals*, **13**: 1–15. [CrossRef](#)
- Kiroğlu, Y., C. Callı, N. Karabulut, C. Oncel. 2010. Intracranial calcifications on CT. *Diagnostic and Interventional Radiology*, **16** (4): 263–269.
- Koval, G. Yu. 1984. *X-Ray Diagnosis of Diseases and Injuries of the Skull*. Health, Kyiv, 1–376. [In Russian]
- Kruska, D. C. T., V. E. Sidorovich. 2003. Comparative allometric skull morphometrics in mink (*Mustela vison* Schreber, 1777) of Canadian and Belarus origin; taxonomic status. *Mammalian Biology*, **68**: 257–276. [CrossRef](#)
- Mead, J. G., R. E. Fordyce. 2009. *The Terian Skull: A Lexicon with Emphasis on the Odontocetes*. Smithsonian contributions to zoology, Washington, 1–248. [CrossRef](#)
- Niemiec, B. A. 2013. *Veterinary periodontology*. John Wiley & Sons, Inc., 1–358. [CrossRef](#)
- Oz, H. S., D. A. Puleo. 2011. Animal Models for Periodontal Disease. *Journal of Biomedicine and Biotechnology*: 1–8. [CrossRef](#)
- Roy, S., N. Reid, R. A. McDonald. 2009. *A Review of Mink Predation and Control in Ireland*. National Parks and Wildlife Service, Department of the Environment, Heritage and Local Government. Dublin, Ireland, 1–63. (Series: Irish Wildlife Manuals; No. 40).
- Sidorovich, V. E. 1993. Reproductive plasticity of the American mink (*Mustela vison*) in Belarus. *Acta Theriologica*, **38**: 175–183. [CrossRef](#)
- Savarin, A. A. 2015. *Pathology of the skull of the Erinaceus concolor roumanicus, living on the territory of Belarus*. BelGUT, Gomel, 1–190. [In Russian]
- Sidorovich, V. E. 1997. *Mustelids in Belarus. Evolutionary Ecology, Demography and Interspecific Relationships*. Zolotoy uley, Minsk, 1–279. [In Russian]
- Stavrou, Z.-E., 2021. *Prevalence of Teeth and Jaw Pathologies in Wild Minks in Lithuania*. Master thesis of Integrated Studies of Veterinary Medicine. Lithuanian university of health sciences, Kaunas, 1–51.
- Tumlison, R., T. L. Tumlison. 2019. Occurrence of the Sinus Nematode *Skrjabinigylus* sp. (Nematoda: Metastrongyloidea) Inferred from Sinus Lesions in Arkansas Mustelidae and Mephitidae, with Review of Relevant Literature. *Journal of the Arkansas Academy of Science*, **73**: 6–12. [CrossRef](#)
- Ulevičius, A., V. Sidorovich, G. Lauzhel. 2001. Specificity of non-metric parameters of American mink (*Mustela vison*) population in relation to habitat differences in Belarus. *Mammalian Biology*, **66**: 35–47.
- Valnisty, A. A., K. V. Homel, E. E. Kheidorova, A. V. Shpak, A. V. Nikiforov. 2020. Molecular genetic polymorphism of American mink populations (*Neovison vison*) in model fur farms and on the adjacent territories in Belarus. *Doklady of the National Academy of Sciences of Belarus*, **64** (6): 685–693. [In Russian] [CrossRef](#)
- Wahl, L., J. Iwanaga, A. B. Chabot, A. S. Dumont, R. S. Tubbs. 2020. Hypoplasia of the Tentorium Cerebelli: Case Report and Review of the Literature. *Kurume medical journal*, **67**: 49–52. [CrossRef](#)
- Zschille, J., D. Heidecke, M. Stubbe. 2004. Verbreitung und Ökologie des Minks — *Mustela vison* Schreber, 1777 (Carnivora, Mustelidae) — in Sachsen-Anhalt. *Hercynia N. F.*, **37**: 103–126.