

UDC 597.0/5–14

MORPHOFUNCTIONAL ADAPTION OF THE RENAL TISSUE OF *ACIPENSER RUTHENUS* (ACTINOPTERYGII, ACIPENSERIFORMES) UNDER TRANSFORMED HABITATION CONDITIONS

M. S. Koziy

Kherson State Agricultural University
R. Luxembourg str., 23, Kherson, 73006 Ukraine
E-mail: office@ksau.kherson.ua

Morphofunctional Adaption of the Renal Tissue of *Acipenser ruthenus* (Actinopterygii, Acipenseriformes) Under Transformed Habitation Conditions. Koziy, M. S. — The morphofunctional state of the mesonephros of the sterlet (*Acipenser ruthenus* Linnaeus, 1758) from the lower reach of the Dnieper river has been studied through the light optical method. The adaptive changes in the structure-functional elements of the mesonephros nephrons have been observed. Among the most perceivable shifts are focal hemorrhage of the reticulo-myeloid tissue, swelling of the epithelium and inflammatory processes. The abnormalities reported are a response to the negative impact of the wastewater constituents.

Key words: nephrons, adaptation, renal corpuscles, convoluted tubules, epithelium.

Морфофункциональная адаптация почечной ткани *Acipenser ruthenus* (Actinopterygii, Acipenseriformes) под влиянием измененных условий обитания. Козий М. С. — Светооптическим методом изучено морфофункциональное состояние мезонефроса стерляди (*Acipenser ruthenus* Linnaeus, 1758) из низовьев р. Днепр. Отмечены адаптивные изменения в структурно-функциональных элементах нефронов туловищной почки. К наиболее ощутимым сдвигам можно отнести очаговые кровоизлияния в ретикуломиелоидной ткани, отёчность эпителия и воспалительные процессы. Отмеченные нарушения являются ответной реакцией на негативные воздействия компонентов сточных вод.

Ключевые слова: нефрон, адаптация, почечные тельца, извитые канальцы, эпителий.

Introduction

Elucidation of the mechanisms of fish adaptation to different biotic and abiotic factors and detection of anomalies in conditions of anthropogenic pollution of water areas is an important part in solving the problem of interaction of organism and environment. Kidneys are important markers of fish contamination because of its indispensability in maintaining homeostasis (water-salt balance, the formation of nonspecific and specific immunity, removing metabolic waste and xenobiotics (Akoev, 1984). In spite of sufficient study of fish mesonephros structure of different ecological groups (Natochin, 1983; Lepilina, 2007; Lapirova, 2009), some issues (data) of intracellular mesonephros transformation in changing habitat remains controversial. Thus the results of such research can determine the theoretical value of adaptive modifications to the natural environmental factors and effects of toxicants of different nature.

Material and methods

The mature adults of starlet (*Acipenser ruthenus* Linnaeus, 1758), 17 ♂, Antonovka, lower reach of the Dnieper River, 15.07.2012 (Koziy leg.) (KSAU) were used as the experimental material for the research layout. The fish was caught with set of stationary nets with a mesh of 40–180 mm. In the process of catching the species (Bogutskaya, Naseka, 2004) age, gender (Bryuzgin, 1969) were identified.

The structure of the mesonephros was chosen as the basis for histological evaluation of the material. The laboratorium inspection of the material was carried out by the author with using of the original equipment and techniques specifically designed to the histological diagnosis of aquatic organisms' tissues (Koziy, 2009), with utilization of the high-end optical equipment («E. Leitz Diaplan», Germany).

Results and discussion

Mesonephros of fish includes three main elements: 1 — intratubular reticulo-myeloid tissue; 2 — areolar tissue; 3 — nephrogenic tissue. The peculiar structure of the sturgeons' kidneys is the inhomogeneity in the structure of the nephron, which manifests itself in varying sizes of the renal glomerules, loop diameters of the proximal and distal nephron, differences in the epithelium structure and height.

A sterlet's renal corpuscle is formed of a capillar glomerule in the cavity of Bowman-Shumlyansky's capsule. The form of the mesonephric corpuscles of this species is mostly round (95 %), less often — elliptical (5 %). The square of the corpuscles in norm was in the range of $113.6\text{--}126.8 \pm 27.5 \mu\text{m}^2$. The square of the histological sections of the urinary space was about $24.8 \pm 7.61 \mu\text{m}^2$.

It's found that the morphology of the proximal convoluted tubules of the nephron can be substituted in two versions: a low epithelium ($4.2\text{--}5.8 \mu\text{m}$) in combination with a broad and rounded tubule lumen, or a high epithelium ($12.4\text{--}18.3 \mu\text{m}$) with a narrow lumen. The fluctuation of the states indicates a definite shift in the functional activity of the epithelial cells and some tubule lumen dilatation with the glomerular filtrate.

The cell surface facing into the tubule lumen is covered with a distinctive brush border. The cytoplasm of the cells of the proximal nephron is as a rule turbid due to the presence of a small amount of pigments and salts (fig. 1).

The epithelium cores are round, predominantly oriented in the direction of the basal membrane. The chromatin is in the form of irregularly interspersed grains. The protein mass is observed in the convoluted tubules lumen, what is the norm.

The intermediate section of the nephron is inlayed with the cuboidal epithelium, but the cells are comparatively lower and brush border naked. Nucleus is elliptical, optically

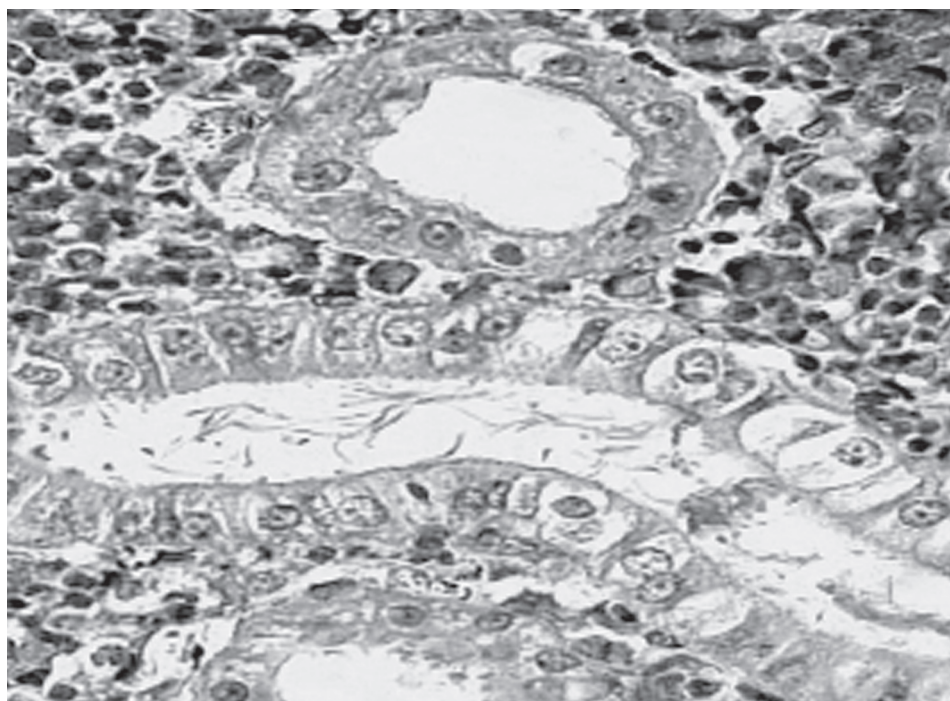


Fig. 1. The normal structure of the sterlet's mesonephros. Ehrlich's hematoxylin, Hart's fuchselin. $\times 200$.

Рис. 1. Нормальная структура мезонефроса стерляди. Гематоксилин Эрлиха, фукселин Харта. $\times 200$.

dense. The cytoplasm of the cubic cells forming the wall of the distal nephron is light. The cells are also brush border naked.

Studies of the fish mesonephroses of from the discharge points showed that the square of the renal cells was increased by 18–23 %, moreover the volume of the urinary space was absent in some cases. The epithelium of the proximal nephron is swollen; the cytoplasm of the cells is turbid. The exfoliation of epithelial cells off the basement membrane is often fixed precisely in this portion (fig. 2).

Degenerative changes in the nephron are accompanied by a variety of nephron vascular disorders, often in the form of the abrupt afferent arteriolar dilatation (fig. 3).

Transformation of the renal corpuscles is often characterized by the abrupt dilatation of the loops and their overflow with blood, the occurrence of adhesions between the capillary loops.

Bleeding into the inter-tubular tissue is revealed on the histological preparations accompanied by a local accretion of haemosiderin. In the most severe cases necrosis of the renal corpuscle is revealed (fig. 4).

The structural elements are destroyed and disappear under chronic long-term impact; and proliferating connective tissue occupies their place (fig. 5).

Thus, the basis of the fish's kidneys adaptation in polluted water is the structural heterochronism of the nephrons and ability of the rearrangements of the cells of the renal corpuscles and tubules in the changing living environment. The pyknotic nucleus, the grain structure of the cytoplasm, the progressive increase in the number and size of the vacuoles in the epithelium are the signs of abnormality. The presence of the pigment in combination with the granular degeneration indicates nephrolithiasis occurred in the fish (Onishchenko, 1991).

Apparently the histomorphological changes in the fish kidneys are closely connected with the duration of the toxicants impact and the set hereof. One of the reasons is poison-

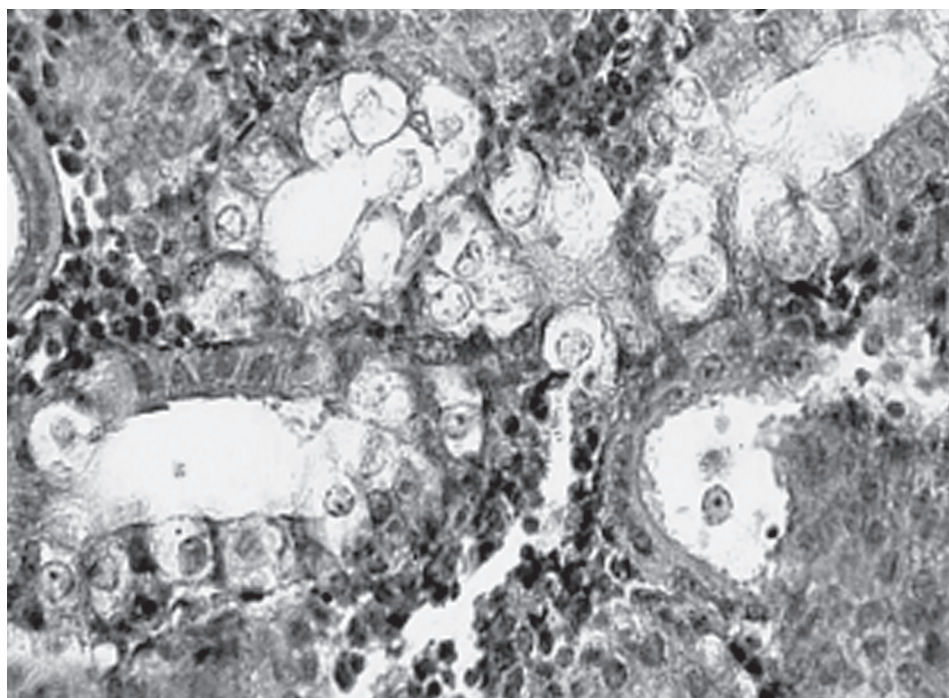


Fig. 2. Changes in the histological structure of the proximal nephron of the sterlet's mesonephros. Ehrlich's hematoxylin, Hart's fuchselin. $\times 200$.

Рис. 2. Изменения в гистологической структуре проксимального отдела нефрона мезонефроса стерляди. Гематоксилин Эрлиха, фукселин Харта. $\times 200$.

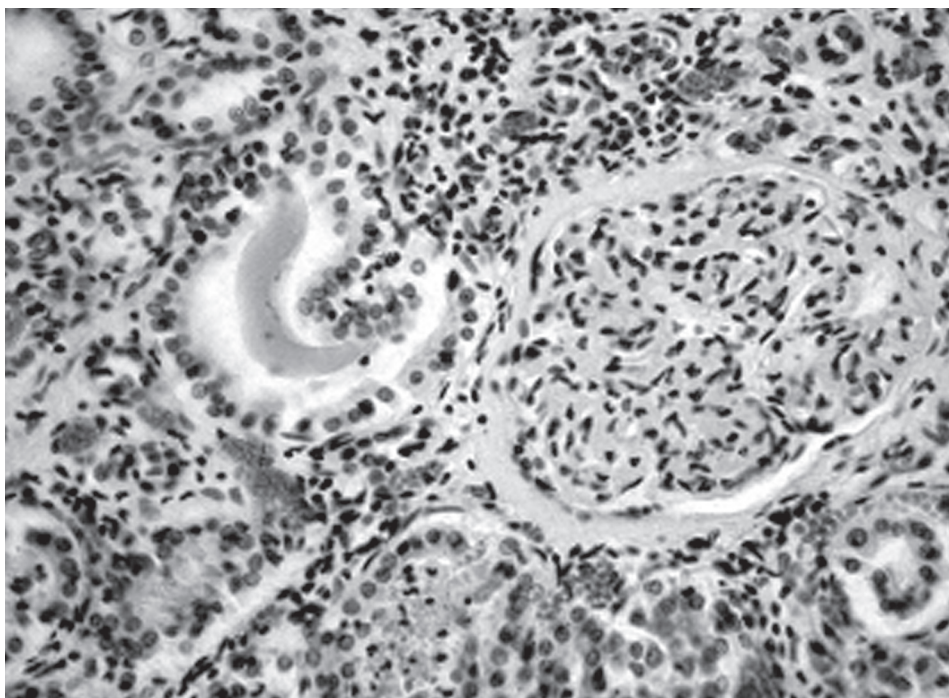


Fig. 3. Degenerative changes in the renal corpuscles of the sterlet's mesonephros. Ehrlich's hematoxylin, Hart's fuchselin. $\times 100$.

Рис. 3. Дегенеративные изменения в почечных тельцах мезонефроса стерляди. Гематоксилин Эрлиха, фукселин Харта. $\times 100$.

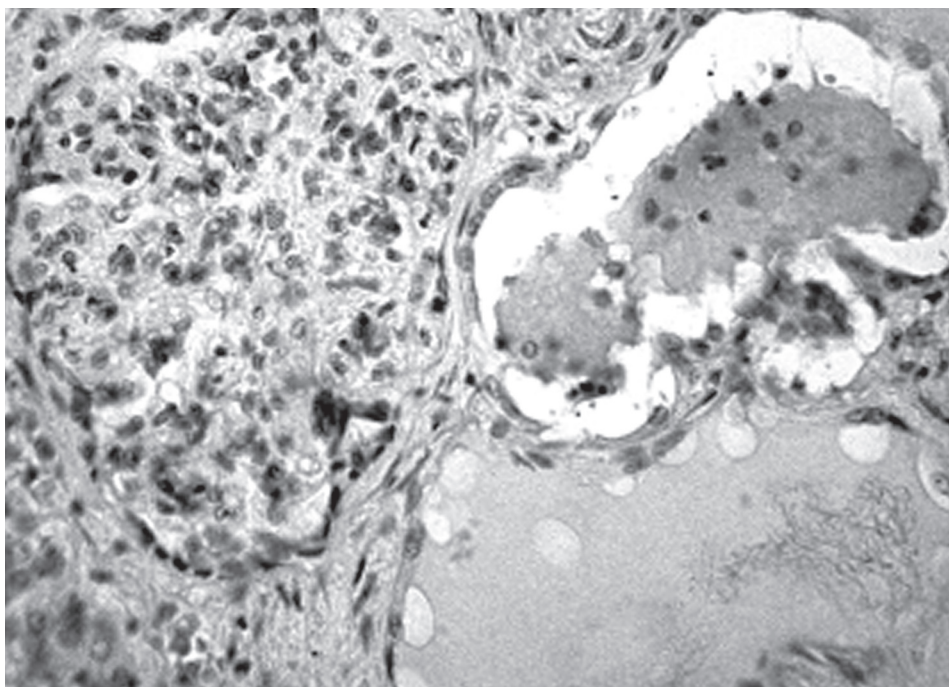


Fig. 4. Necrosis of the renal corpuscle of the sterlet's mesonephros. Ehrlich's hematoxylin, Hart's fuchselin. $\times 70$.

Рис. 4. Некроз почечного тельца мезонефроса стерляди. Гематоксилин Эрлиха, фукселин Харта. $\times 70$.

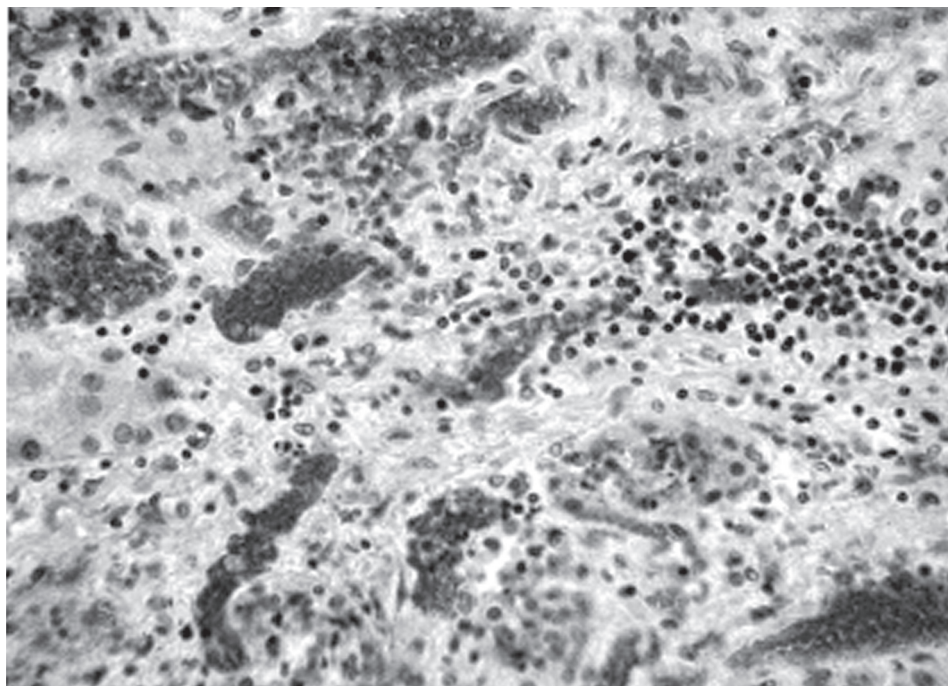


Fig. 5. The total sterlet's mesonephrolysis. Ehrlich's hematoxylin, Hart's fuchselin. $\times 100$.

Рис. 5. Тотальное разрушение мезонефроса стерляди. Гематоксилин Эрлиха, фукселин Харта. $\times 100$.

ing with heavy metal salts (Hg, Pb, Cr etc.). The influence of the toxic substances on the epithelium of the convoluted tubule results from its reabsorption ability (Lesnikov, 1987).

At the same time regeneration of the tubule epithelial and glomerular apparatus occurs in the kidneys. Reversible changes are traced as increasing size of extant corpuscles providing compensation for the lost functions of the organ.

Conclusions

The adaptive responses of the nephrogenic tissue are expressed in the variability in the tubules diameter as a compensation for the reduced glomerular filtration; change of the vascular blood supply of the kidney; changes in size, shape and functional activity of the glomerules.

Some observed morpfo pathology indicates severe functional changes in the organ and the potential toxicopathy of the fish due to disorder in the excretion of the metabolic wasts.

Fluctuation in the structure of mesonephros allows to suppose decreasing in the resistance of a fish to various diseases.

The results of the studies on morphofunctional abnormalities in the kidneys of the fish in the natural environment can serve an indicator of the unfavorable changes in the environment, which leads to the regressive condition of the exploited populations.

References

- Akoev, I. G., Motlokh, N. N. Biophysical analysis of the pre-pathological states and pre-leukemic conditions. — Moscow : Nauka (Science), 1984. — 288 p. — Russian : Акоев И. Г., Мотлох Н. Н. Биофизический анализ предпатологических и предлейкозных состояний.
- Vogutskaya, N. G., Naseka, A. M. Catalogue of Agnathans and Fishes of fresh and brakish waters of Russia with comments on nomenclature and taxonomy. — Moscow : KMK Scientific Press Lt., 2004. — 392 p. — Russian : Богдацкая Н. Г., Насека А. М. Каталог бесчелюстных и рыб пресных и солоноватых вод России с номенклатурными и таксономическими комментариями.

- Bryuzgin, V. L.* Methods for studying of the growth of fish by scales, bones and otoliths. — Kyiv : Naukova dumka, 1969. — 187 p. — Russian : *Брюзгин В. Л.* Методы изучения роста рыб по чешуе, костям и отолитам.
- Koziy, M. S.* Assessment of the current histological techniques and ways to improve the study of fish fauna. — Kherson : Oldi-plus, 2009. — 310 p. — Russian : *Козий М. С.* Оценка современного состояния гистологической техники и пути совершенствования изучения ихтиофауны.
- Lapirova, T. B., Zobotkina, Ye. A., Balabanova, L. V.* The comparative analysis of immunophysiological mechanisms response on the unfluence of cadmium with the yearlings of Siberian sturgeon and carp // Questions fisheries. — 2009. — **10**, N 1 (37). — P. 81–91. — Russian : *Ланирова Т. Б., Заботкина Е. А., Балабанова Л. В.* Сравнительный анализ иммунофизиологических механизмов реагирования молоди осетра сибирского и карпа обыкновенного на действие кадмия.
- Lepilina, I. N.* The development of the mesonephros in the sturgeon larvae // J. Ichthyology. — 2007. — **47**. — P. 86–92. — Russian : *Лепилина И. Н.* Развитие мезонефроса у личинок осетровых рыб.
- Lesnikov, V. A., Chimareva, T. V.* Pathological and histological analysis of the state of fish under field and experimental toxicology studies // Ichthyological research methods. — Moscow : Nauka, 1987. — P. 80–81. — Russian : *Лесников В. А., Чимарёва Т. В.* Патолого-гистологический анализ состояния рыб при полевых и экспериментальных токсикологических исследованиях.
- Natochin, Yu. V.* The evolution of the water-salt metabolism and of the kidney. — Leningrad : Nauka, 1983. — P. 371–426. — Russian : *Наточин Ю. В.* Эволюция водно-солевого обмена и почки.
- Onishchenko, L. S.* Histological examination of the fish of the various water spaces of the Ladoga Lake: Abstract of the II All-Union Conference on Fisheries Toxicology dedicated to the 100th anniversary of the water quality problems in Russia. — St. Petersburg : SPb. press., 1991. — P. 81–83. — Russian : *Онищенко Л. С.* Гистологическое исследование рыб различных акваторий Ладожского озера.

Received 1 October 2013

Accepted 8 April 2014